



## ACUTE A RARE CASE OF ABDOMINAL HYDATIDOSIS

Satender Singh<sup>1</sup>, Divya. J<sup>2</sup>

<sup>1</sup>Post graduate, <sup>2</sup>Assistant professor, Department of Radiology, Shridevi Institute of Medical sciences and Research Hospital, Tumkur, Karnataka

### ABSTRACT

Hydatid disease (HD)—also called hydatidosis, echinococcal disease or echinococcosis is a zoonosis caused by tape-worms of the genus *Echinococcus*. The disease is usually acquired when contaminated water or food that contains the parasitic larvae of echinococci is ingested. CT and MRI are ways to define better cyst calcifications; they are crucial for determining lesion viability and in turn, selecting the appropriate treatment. CT and MR imaging have important roles in the evaluation of extra-hepatic HD, as they enable better assessment of the extent of larger lesions and aid in establishing the relationships of the cyst with surrounding structures. A 35 years old female patient was admitted with a history of abdomen distension of 6 months and abdomen pain of 2 weeks at Shridevi Institute of Medical Sciences and Research Hospital, Tumkur. To evaluate for the symptoms, USG was done followed by CT and MR which showed multiple large well defined cystic lesion with multiple thin septae, calcifications, debris with pelvic extension. Hydatid disease primarily affects the liver and typically demonstrates well-known, characteristic imaging findings. Hepatic hydatidosis are common but is rare to see all type of hydatidosis and with all stages at same time.

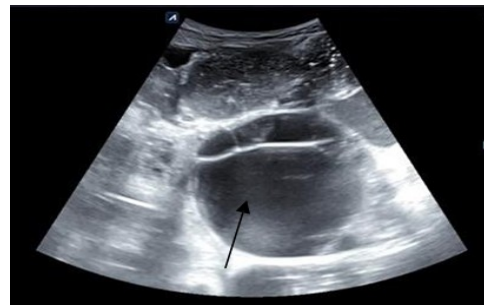**Keywords:** Hydatid cyst; Hydatidosis

### INTRODUCTION

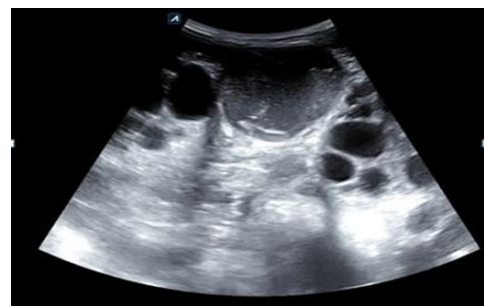Renal tubular acidosis is a constellation of syndromes arising from different derangements of tubular acid transport [1]. Common clinical presentations of dRTA in the paediatric age group include polyuria, nocturia, failure to thrive, constipation, abnormal breathing and nephrolithiasis. Though persistent hypokalemic is frequently seen in dRTA, hypokalemic muscular paralysis is uncommon and rarely described in children. Acute Flaccid Paralysis with symptoms of hypokalaemia and paralysis which was initially mistaken for the Guillain-Barre syndrome, however it was later diagnosed as Distal Renal Tubular Acidosis (dRTA).

### CASE REPORT

A 35 years old female patient was admitted with a history of abdomen distension of 6 months and abdomen pain of 2 weeks at Shridevi Institute of Medical Sciences and Research Hospital, Tumkur. To evaluate for the symptoms, USG was done followed by CT and MR which showed multiple large well defined cystic lesion with multiple thin septae, calcifications, debris with pelvic extension.



**Fig 1.** Showing large well defined cystic lesion with multiple thin septae.



**Fig 2.** Showing Sandstorm cystic lesion.



eISSN: 2583-7761

**Correspondence:** Dr Satender, Shridevi Institute of Medical sciences and Research Hospital, Tumkur, Karnataka, [takasatendersinghpl@gmail.com](mailto:takasatendersinghpl@gmail.com)

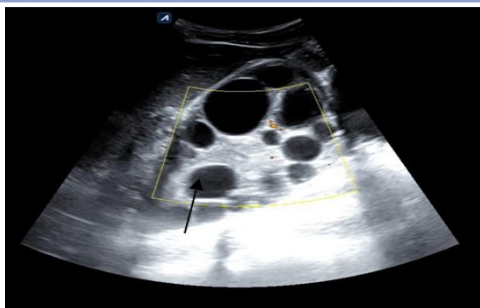


Fig 3. Showing spoke wheel appearance.

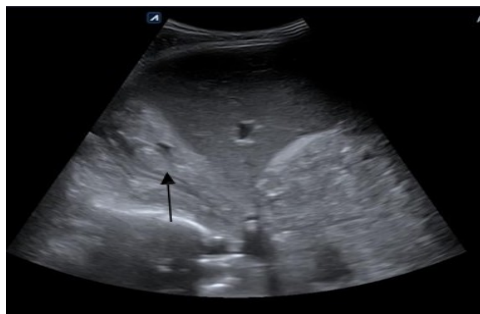


Fig 4. Showing Detached membranes within the cyst

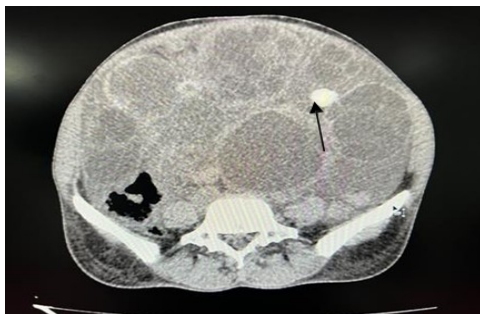


Fig 5. Showing NCCT axial view with few calcific cyst and cyst with thick-walled calcification

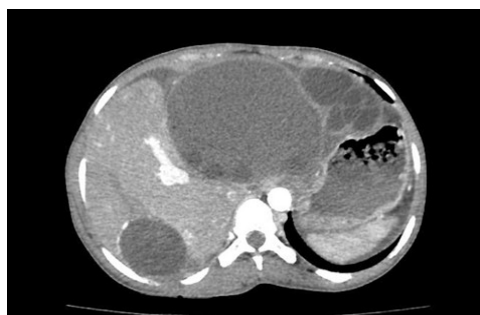

Fig 6. Showing CT axial image in arterial phase with multiple well-defined, round to oval cystic lesions with thin hyperdense internal septae within a cyst.

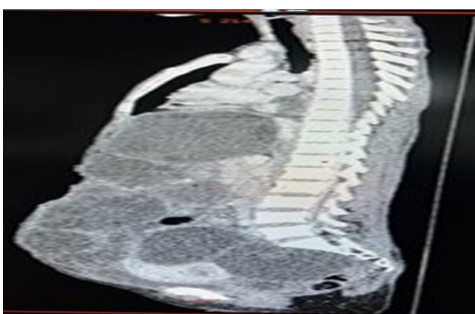


Fig 7. Showing Sagittal image with pelvic extension.

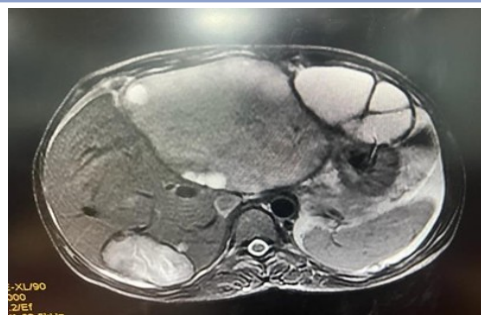

Fig 8. Showing MRI T2 axial view with multiple hyperintense cystic lesions with variable sizes showing few thin septae within

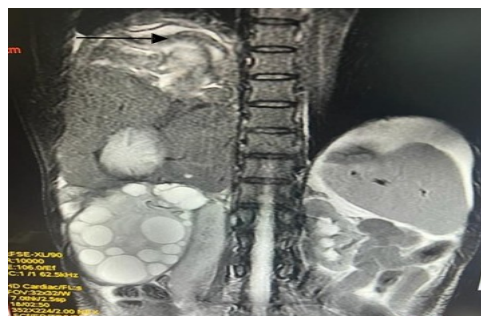

Fig 9. Showing MRI T2 coronal section with liver cyst with detached membranes.



Fig 10. Showing Gross specimen post OT with vesicles resemble a bunch of grapes.

## DISCUSSION

Hydatid disease is a parasitic infection present all over the world. Though mostly common in regions of eastern Europe, south Africa, middle east, south America, Australia and Mediterranean where cattle rearing is common. Liver and lungs are often end dissemination of the cysts while other places like mediastinum, diaphragm, cardiac, smooth and skeletal muscle, abdominal, omentum, peritoneal and chest wall are involved rarely. The disease is asymptomatic and found accidentally[1,2]. Depending upon the size and site various symptoms can occur. Diagnosis is made by history, physical examination and serological test and imaging. Hydatid cyst is a slow growing and may have history of close animal contact. Physical examination shows mass and hydatid thrill [3,4]. Imaging is done by USG, CT and MRI. USG showed extensive well-defined round to oval cystic hypoechoic cystic lesion and CT showed extensive well defined rounded to oval cystic lesions with thin hyperdense internal septae

within a cyst showing a spoke wheel pattern are seen scattered in entire peritoneal cavity in abdomen and pelvis. Treatment is mainly surgical [5].

## CONCLUSION

Hydatid disease primarily affects the liver and typically demonstrates well-known, characteristic imaging findings. Hepatic hydatidosis are common but is rare to see all type of hydatidosis and with all stages at same time. There are many potential local complications, and secondary involvement due to hematogenous dissemination may be seen in almost any anatomic location. Familiarity with atypical manifestations of hydatid disease may be helpful in making a prompt, accurate diagnosis.

## REFERENCES

1. Iván Pedrosa, Antonio Saíz, Juan Arrazola, Joaquín Ferreirós, César S. Pedrosa. Hydatid Disease: Radiologic and Pathologic Features and Complications. *RadioGraphics*. 2000; 20(3):1-3
2. Karavias DD, Vagianos CE, Kakkos SK, et al. Peritoneal echinococcosis. *World J Surg* 1996; 20:337–340. 22.
3. Ulualp KM, Aydemir I, Senturk H, et al. Management of intrabiliary rupture of hydatid cyst of the liver. *World J Surg* 1995; 19:720–724. 23.
4. Khaldi F, Braham N, Ben Chehida F, et al. Hepatic hydatidosis and portal hypertension in children: is it the Budd-Chiari syndrome? *Ann Pediatr (Paris)* 1993; 40:631–634. 24.
5. Gil-Egea MJ, Alameda F, Girvent M, Riera R, Sitges-Serra A. Hydatid cyst in the hepatic hilum causing a cavernous transformation in the portal vein. *Gastroenterol Hepatol* 1998; 21:227–229.